

# Case reports

---

*Acta Chir Belg*, 2013, **113**, 40-42

## A Very Nervous Inguinal Floor : Report of a Case

H. Kulacoglu<sup>1,3</sup>, T. Sen<sup>2</sup>, I. Ozyaylali<sup>3</sup>, A. Elhan<sup>2</sup>

<sup>1</sup>Diskapi Yildirim Beyazit Teaching and Research Hospital, Department of Surgery ; <sup>2</sup>Ankara University School of Medicine, Department of Anatomy ; <sup>3</sup>Ankara Hernia Center, Ankara, Turkey.

**Abstract.** Chronic pain after inguinal hernia repair with prosthetic meshes is recorded in some patients. Although the exact etiology of the pain is not fully understood, it can be related to the trauma to the regional nerves. It is possible to involve these nerves by injuring, suturing, stapling, tacking or compressing them during the operation. Therefore, a delicate surgical approach to the inguinal floor with correct identification of three nerves is necessary for patient comfort at early and late postoperative period. We herein report a surgical view of an inguinal floor which are very rich of neural structures in a patient undergo an elective inguinal hernia repair. The number of the main nerve bundles was excessive, and they were thicker than generally met. This kind of anatomic variations may create a difficulty for repair with prosthetic material. The identification of the nerve structures was hard at first sight and the correct identification was only made by consulting the surgical picture with a senior anatomist.

### Introduction

Prosthetic mesh repairs for groin hernias have become widespread because of technical simplicity and low recurrence rates. Although their complication rates also low, some patients may complain about chronic pain in the inguinal region after surgery. This problem was, probably, first named by Heise and Starling as “mesh inguinodynia” in 1998 (1). The incidence of chronic pain after inguinal hernia repairs has been reported to be as high as 54% (2). Recently AROORI and SPENCE suggested that this issue should be involved in the informed consent forms of all patients undergoing any type of hernia repair (3).

The exact etiology of postherniorraphy inguinodynia is not fully understood. The source of the pain has been classified into three types : non-neuropathic, neuropathic, and nerve injuries (4). The first one may be arose from a periostal reaction to fixation sutures, scar tissue or mechanical pressure of folded mesh. Other two types are directly related to the regional nerves as hidden in their terms.

The nerves of the inguinal region that surgeons encounter during hernia repair are iliohypogastric, ilioinguinal and genitofemoral nerves. It is possible to involve these nerves by injuring, suturing, stapling, tacking or compressing them during the operation. Therefore, correct identification of three nerves by means of a good knowledge about the area and a careful mesh placement during

open or endoscopic repairs are recommended for patient comfort at early and late postoperative period (5, 6).

Nevertheless regional nerves may show anatomic variations from the patterns presented in anatomy textbooks. These variations will make the identification and protection of the nerves difficult for the surgeons. We herein present a surgical view from an inguinal hernia repair. The inguinal floor of the patient were very rich of neural structures and this anatomy itself was a difficulty for repair with prosthetic material.

### Case Report

Thirty-three-year-old male patient was prepared for an elective inguinal hernia repair in day-case basis. Local anesthesia was applied by using step-by-step infiltration technique. External oblique aponeurosis was opened and inguinal floor entirely exposed. An unusual regional nerve anatomy was encountered. The number of the main nerve bundles was excessive, and they were thicker than generally met. It was really hard to identify and named the whole picture at first sight. A high resolution photograph was taken to evaluate the nerve distribution later on together with a senior anatomist who has special interest to the inguinal region (The eventual evaluation was presented in Figure 1).

The further necessary dissection and mesh placement was completed without any harm to the nerves. An uneventful postoperative recovery was recorded. The

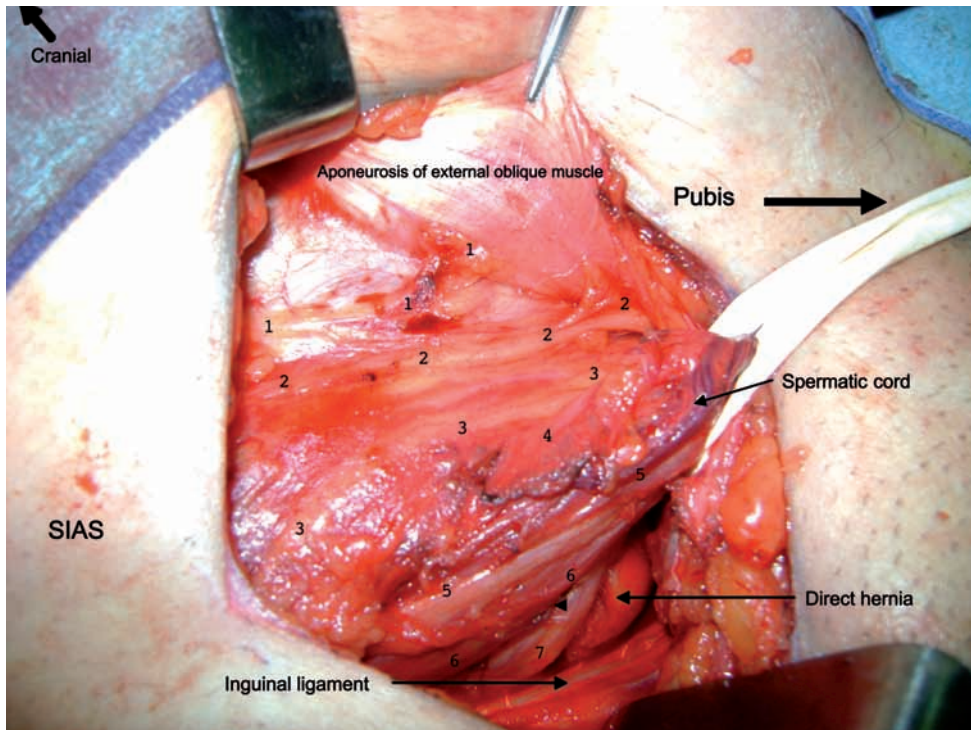


Fig. 1

The surgical anatomy during the operation. The nerve structures are identified as follow : 1. subcostal nerve (or iliohypogastric nerve branch), 2. iliohypogastric nerve, 3. ilioinguinal nerve branch, 4. ilioinguinal nerve branch, 5. ilioinguinal nerve (or genital branch of genitofemoral nerve), 6. ilioinguinal nerve branch (or genital branch of genitofemoral nerve), 7. genital branch of genitofemoral nerve.

patient has not experienced any regional pain within a one-year period.

### Discussion

Regional nerves of the inguinal region have gained importance because of the increase in postoperative pain following groin hernia repairs. Prof. AMID of the Lichtenstein Hernia Institute suggests that the nerves distributed over the inguinal floor should be as kindly as treated like the laryngeal nerves of a thyroidectomy field (congress speeches, personal communication). In fact, the only concern about these nerves is not pain, but some patients complain about numbness and paresthesia after surgery. All three nerves give sensory branches to a wide skin area including hypogastric region, gluteal region, proximal, medial and lateral aspects of the thigh, supra-pubic region, and external genitalia (7, 8).

It is usually easy to identify and protect the nerves for a surgeon with an adequate anatomical knowledge and surgical experience. However, anatomical variations make that more difficult even for senior surgeons. It has been reported that the course of the branches of these three nerves may show variations from classical anatomical texts in almost 50% of the dissections (9, 10). The

origin of the nerves at lumbar plexus level may also exhibit differences. BERGMAN reported 10 different types of formation of the ilioinguinal nerve (11). UZMANSEL presented four variations in a 35-year-old female cadaver including a paired ilioinguinal nerve (12). Sometimes, iliohypogastric and ilioinguinal nerves are composed, while iliohypogastric nerve or ilioinguinal nerve may be absent in up to one fourth of the individuals (7, 13).

Typically, all three nerves travel on the psoas major muscle after originating from the lumbar plexus. They pierce transversalis fascia and each follows its own course in the inguinal region. Iliohypogastric nerve traverses through the oblique muscles to which it supplies motor branches. It generally pierces the internal oblique muscle lateral to the Lichtenstein incision and courses almost horizontally and ventrally to this muscle to perforate the external oblique aponeurosis (13). Ilioinguinal nerve pierces the internal oblique muscle lateral to the incision in almost one half of the cases, while medial in the other half. It classically travels over or parallel to the spermatic cord just dorsally to the external aponeurosis and is easy to identify in the majority. Both nerves may give smaller branches and make anastomosis with each other. Cutaneous branches of the ilioinguinal nerve also incorporate within the genitofemoral nerve (8).

Genital branch of the genitofemoral nerve is the most difficult to identify during a hernia repair. It enters the surgical field a few millimeters caudally from the internal ring together with the cremasteric artery and vein (13). It has been stated that this nerve can be seen within the cord just under the blue line created by cord veins.

Although some variations and absence of the iliohypogastric and ilioinguinal nerves rather frequent, duplications are rare. AL-DABBAGH found an accessory iliohypogastric or ilioinguinal nerve in 3 of 64 cases. NDIAYE reported two ilioinguinal nerves in one of 100 inguinal dissections (14). Variations of the ilioinguinal nerve have generally reported about its branching around the superficial ring (6, 14).

A neglected structure for inguinal region is subcostal nerve, also known as 12.thoracic nerve. This nerve may be met in the inguinal floor during hernia surgery (4). The structure that marked as a possible subcostal nerve in Figure 1 was traced on the internal oblique muscle during the operation, and a separate muscle piercing from the ilioinguinal nerve was observed.

In the present case, it could not be possible to identify the exact origin of the nerves or nerve branches owing to the natural progress of the routine hernia repair technique. This is the difference between surgical practice and anatomical cadaver dissection. Therefore, we could not name these anatomical structures entirely. This was really an exceptional view that the first author have not met during his over 20-year of surgical experience including thousands of groin hernia repairs.

It is known that there are discrepancies between surgeons and anatomists in interpreting some anatomical regions. Surgeons are familiar with fresh picture of surgical fields, whereas anatomist are very experienced about the thorough course of a structure from the origin to end. In the present case, an agreement between the surgeon and the anatomist was hardly established, while some structures remained arguable.

This complex distribution of the regional nerves surely creates a difficulty for the surgeons during the placement and the fixation of the mesh. All the sutures, staples or tackers should be placed under direct vision to provide an uneventful repair. Although it was not necessary in the present case, it can be considered to excise a nerve or its branches if they obstruct a proper mesh placement. This approach has been found to be innocent in some recent controlled studies (15, 16).

We herein would like to present a very interesting view from a hernia repair. Although the present case is an exception, the importance of the regional nerves in

hernia repairs worth a mention always. The naming of the presented nervous structures is open for the contributions and the criticism of the readers.

## References

- HEISE C. P., STARLING J. R. Mesh inguinodynia : a new clinical syndrome after inguinal herniorrhaphy ? *J Am Coll Surg*, 1998, **187** : 514-518.
- POOBALAN A. S., BRUCE J., SMITH W. C., KING P. M., KRUKOWSKI Z. H., CHAMBERS WA. A review of chronic pain after inguinal herniorrhaphy. *Clin J Pain*, 2003, **19** : 48-54.
- AROORI S., SPENCE R. A. Chronic pain after hernia surgery – an informed consent issue. *Ulster Med J*, 2007, **76** : 136-140.
- AMID P. K. Causes, prevention, and surgical treatment of post-herniorrhaphy neuropathic inguinodynia : triple neurectomy with proximal end implantation. *Hernia*, 2004, **8** : 343-349.
- DA COSTA P. M. Laparoscopic totally extra-preperitoneal hernia repair (TEP). Technical aspects. Ten rules for a successful TEP procedure. *Acta Chir Belg*, 2009, **109** : 133-135.
- ANLOAGUE P. A., HUIJBREGTS P. Anatomical variations of the lumbar plexus : a descriptive anatomy study with proposed clinical implications. *J Man Manip Ther*, 2009, **17** : E107-E114.
- DA COSTA P. M. Complications and recurrences after different types of hernia repair : how to deal with it ? *Acta Chir Belg*, 2009, **109** : 36-41.
- RAB M., EBMER J., DELLON A. L. Anatomic variability of the ilioinguinal and genitofemoral nerve : implications for the treatment of groin pain. *Plast Reconstr Surg*, 2001, **108** : 1618-1623.
- SALAMA J., SARFATI E., CHEVREL J. P. The anatomical bases of nerve lesions arising during the reduction of inguinal hernia. *Surg Radiol Anat*, 1983, **5** : 75-81.
- AL-DABBAGH A. K. R. Anatomical variations of the inguinal nerves and risks of injury in 110 hernia repairs. *Surg Radiol Anat*, 2002, **24** : 102-107.
- BERGMAN R. A., AFIJI A. K., MIYAUCHI R. Variations in formation of ilioinguinal nerve. <http://www.anatomyatlases.org/AnatomicVariants/NervousSystem/Text/IlioinguinalNerve.shtml>.
- UZMANSEL D., AYTEKIN M., KARA A. Multiple variations of the nerves arising from the lumbar plexus. *Neuroanatomy*, 2006, **5** : 37-39.
- LANGE J. F., WIJSMULLER A. R., VAN GELDERE D., SIMONS M. P., SWART R., OOMEN J., KLEINRENSINK G. J. *et al.* Feasibility study of three-nerve-recognizing Lichtenstein procedure for inguinal hernia. *Br J Surg*, 2009, **96** : 1210-1214.
- NDIAYE A., DIOP M., NDOYE J. M., NDIAYE A., MANÉ L., NAZARIAN S. *et al.* Emergence and distribution of the ilioinguinal nerve in the inguinal region : applications to the ilioinguinal anaesthetic block (about 100 dissections). *Surg Radiol Anat*, 2010, **32** : 55-62.
- RAVICHANDRAN D., KALAMBE B. G., PAIN J. A. Pilot randomized controlled study of preservation or division of ilioinguinal nerve in open mesh repair of inguinal hernia. *Br J Surg*, 2000, **87** : 1166-1167.
- SMEDS S., LÖFSTRÖM L., ERIKSSON O. Influence of nerve identification and the resection of nerves 'at risk' on postoperative pain in inguinal hernia repair. *Hernia*. 2010 DOI : 10.1007/s10029-010-0632-9.

Dr. H. Kulacoglu, MD, FACS  
Bahcelievler, 1.cadde, 109/5  
06490, Ankara, Turkey  
hakankulacoglu@hotmail.com